

CASE REPORT

Acute carpal tunnel syndrome secondary to chronic trans-scaphoid perilunate fracture dislocation. Case report

Síndrome del túnel carpiano agudo secundario a luxofractura transescafo perilunar crónica. Reporte de caso

Jorge Luis Rodríguez-Argüello¹  Andrés Julián Arango-Mejía²  Andrés Villa-Henríquez¹  Steven Otálvaro-Noreña³ 

¹ Clínica CES, Orthopedic and Trauma Surgery Service, Medellín, Colombia.

² Clínica CES, Hand Surgery Service, Medellín, Colombia.

³ Universidad de Cartagena, Postgraduate Degree in Orthopedic and Trauma Surgery, Cartagena, Colombia.

Abstract

Introduction: Perilunate injuries are rare, and their severity and frequent underdiagnosis favor the onset of complications such as carpal tunnel syndrome (CTS) or compartment syndrome (CS).

Case presentation: A 53-year-old male was admitted to the emergency department of a secondary care hospital in a rural area of Antioquia (Colombia) due to a crush injury (600 kg) to his right hand. Since bone and joint injuries were ruled out during the initial assessment by means of an X-ray of the hand, he was discharged without being immobilized and with instructions to take pain medication and attend a follow-up appointment with the general medicine service. During the follow-up appointment, two weeks after the accident, the patient reported persistent pain and paresthesia in the first three fingers. In addition, a decrease in the range of motion of the wrist was observed, so a CT scan was requested and the patient was referred to the hand surgery unit, where he was evaluated two weeks later. On physical examination, a positive Tinel's sign was reported, with no findings suggestive of CS, resulting in a diagnosis of CTS. After reviewing previous imaging tests, a dorsal trans-scaphoid perilunate fracture dislocation was identified. Six weeks after the injury, open reduction with internal fixation, reconstruction of the dorsal trans-scaphoid perilunate and dorsal intercarpal ligaments, and carpal tunnel release were performed. Four weeks later, the percutaneous fixation was removed. At the 16-week postoperative follow-up, the patient reported complete resolution of pain and neuropathic symptoms and adequate reintegration to his work activities; there was also complete mobility of the fingers and wrist.

Conclusion: Trans-scaphoid perilunate fracture dislocations are rare injuries that should be suspected after sustaining a high-energy trauma to the carpus, as timely diagnosis and treatment are essential to avoid severe complications such as CTS. Since surgery with open reduction and internal fixation, ligament reconstruction, and carpal tunnel release showed good outcomes in our case, it could be considered a treatment option for patients with chronic trans-scaphoid perilunate fracture dislocations with associated CTS.

Keywords: Fracture Dislocation; Scaphoid Bone; Carpal Tunnel Syndrome; Open Fracture Reduction; Wrist; Trauma (MeSH).

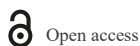Resumen

Introducción. Las lesiones perilunares son poco comunes y su gravedad y frecuente subdiagnóstico favorecen la aparición de complicaciones como el síndrome de túnel carpiano (STC) o el síndrome compartimental (SC).

Presentación del caso. Hombre de 53 años que fue llevado al servicio de urgencias de un hospital de segundo nivel del área rural en Antioquia (Colombia) debido a un trauma por aplastamiento (600kg) en mano derecha. Ya que durante la valoración inicial se descartaron lesiones óseas y articulares mediante radiografía de mano, fue dado de alta sin inmovilización y con indicación de manejo analgésico y asistir a cita de seguimiento con el servicio de medicina general. En cita de seguimiento dos semanas postrauma, reportó persistencia del dolor y parestesias de los primeros tres dedos; además, se observó disminución en los arcos de movilidad de la muñeca, por lo que se solicitó una tomografía computarizada y fue remitido al módulo de cirugía de mano, donde fue evaluado 2 semanas después. Al examen físico, se reportó signo de Tinel positivo, sin hallazgos sugestivos de SC, siendo diagnosticado con STC; luego de revisar las pruebas de imagen previas, se identificó luxofractura transescafo perilunar dorsal. Seis semanas postrauma, se realizó reducción abierta con fijación interna, reconstrucción de los ligamentos escafolunar dorsal e intercarpiano dorsal, y liberación del túnel carpiano. Cuatro semanas después se retiró la fijación percutánea. En el seguimiento a las 16 semanas posoperatorias, el paciente reportó resolución completa del dolor y los síntomas neuropáticos, y reintegración adecuada a su actividad laboral; además, mostró movilidad completa de dedos y muñeca.

Conclusión. Las luxofracturas transescafo perilunares son lesiones infrecuentes que deben sospecharse luego de traumas de alta energía que afectan el carpo, pues su diagnóstico y tratamiento oportunos son fundamentales para evitar complicaciones serias como STC. Ya que el manejo quirúrgico con reducción abierta con fijación interna, reconstrucción de ligamentos y liberación del túnel carpiano mostraron buenos resultados en nuestro caso, podría considerarse como una opción terapéutica en pacientes con luxofracturas transescafo perilunares crónicas con STC asociado.

Palabras clave: Fractura con Luxación; Hueso Escafoides; Síndrome del Túnel Carpiano; Reducción Abierta; Muñeca; Trauma (DeCS).



Open access

Recibido: 04/03/2024

Aceptado: 27/05/2025

Corresponding author: Jorge Luis Rodríguez Argüello. Servicio de Ortopedia y Traumatología, Clínica CES. Medellín, Colombia. E-mail: jorgeluisrodriguez97@outlook.com.

How to cite: Rodríguez-Argüello JL, Arango-Mejía AJ, Villa-Henríquez A, Otálvaro-Noreña S. [Acute carpal tunnel syndrome secondary to chronic trans-scaphoid perilunate fracture dislocation. Case report]. Rev Col Or Tra. 2025;39:e517. English. doi: <https://doi.org/10.58814/01208845.517>.

Cómo citar: Rodríguez-Argüello JL, Arango-Mejía AJ, Villa-Henríquez A, Otálvaro-Noreña S. [Síndrome del túnel carpiano agudo secundario a luxofractura transescafo perilunar crónica. Reporte de caso]. Rev Col Or Tra. 2025;39:e517. English. doi: <https://doi.org/10.58814/01208845.517>.

Copyright: ©2025 The Author(s). This is an open access article distributed under the terms of the [Creative Commons Attribution 4.0 International License](https://creativecommons.org/licenses/by/4.0/), which permits unrestricted use, distribution, and reproduction in any medium, as long as the original author and source are credited.



Introducción

Carpal dislocations and fracture-dislocations are rare injuries that account for between 7 and 10% of carpal injuries, affecting young men most frequently after suffering from a high-energy trauma caused by traffic accidents, falls from height, or sports accidents.^{1,2} Between 14.8% and 25% of perilunate injuries are not diagnosed during initial emergency department care, mainly due to the absence of abnormal signs on X-rays (90% of cases).³

It is important to diagnose these injuries early due to the risk of complications such as progressive carpal instability, post-traumatic arthritis, and acute carpal tunnel syndrome.³ Regarding the latter, it has been reported that perilunate dislocation can exert pressure on the median nerve, causing permanent injury if timely reduction is not performed. A retrospective study involving 33 patients with perilunate injuries treated at a trauma center in the United States between 2014 and 2023 reported that 61% of them sustained a trans-scaphoid perilunate fracture dislocation, while about 50% presented symptoms of median nerve compression.⁴

Chronic trans-scaphoid perilunate fracture dislocation is defined as a dislocation that is diagnosed and treated more than six weeks after suffering the trauma.⁴ Unlike patients with acute injuries, who usually experience pain and swelling in the wrist, patients with chronic injuries typically present with nerve symptoms or tendon ruptures.⁵ Several treatment protocols exist to treat chronic trans-scaphoid perilunate fracture dislocations, all of which aim to achieve anatomical alignment of the carpus, including closed reduction and immobilization, open reduction with internal fixation, staged treatment using an external fixator, carpectomy, and wrist arthrodesis.⁵

The following is the case of a male patient who suffered from acute carpal tunnel syndrome secondary to chronic trans-scaphoid perilunate fracture dislocation in whom satisfactory outcomes were achieved following surgery (open reduction with internal fixation, reconstruction of the dorsal scapholunate and dorsal intercarpal ligaments, and carpal tunnel release).

Case presentation

Clinical findings

A 53-year-old male with no relevant medical history attended the emergency department of a tertiary care hospital in Medellín (Colombia) after suffering a crush injury (approximately 600 kg) to his right hand as a result of a work accident. He presented with pain at rest and edema in his right hand and wrist, as well as limited functionality of this limb. On physical examination, the following was reported: generalized edema in the right hand and wrist, with no apparent deformity or open lesions or wounds on the skin; pain on palpation of the affected area; and radial and ulnar pulses symmetrical to the healthy limb, with capillary refill time <3 seconds. No bone or joint injuries were observed in the X-ray of the right hand and wrist. Considering these findings, the patient was discharged without immobilization and with indications for pain management, sick leave, and outpatient follow-up with the general practitioner.

At the follow-up appointment two weeks after the trauma, the patient reported persistent pain in his right hand and wrist, as well as paresthesia in the first three fingers. Physical examination revealed edema in the right hand and wrist, pain on palpation, hypoesthesia in the first three fingers on the palmar aspect, and decreased range of motion in the wrist (flexion: 20°; extension: 30°; ulnar deviation: 10°; radial deviation: 20°). Therefore, a computed tomography (CT) scan of the right hand and wrist was

requested, and the patient was referred to the hand surgery unit of the orthopedic and trauma surgery department.

Five weeks after the trauma, the patient was assessed by specialists from the hand surgery unit. On physical examination, a positive Tinel's sign was identified (pins and needles sensation after pressing on the median nerve by repeatedly tapping the carpal tunnel with a finger); however, it was not possible to accurately perform the Phalen's maneuver due to pain. No signs or symptoms suggestive of compartment syndrome, such as severe and progressive pain, marked edema, absence of pulse, or pallor, were observed. Given these findings, carpal tunnel syndrome was diagnosed. Upon reviewing the X-rays taken on the day of the trauma (Figures 1 and 2) and the CT scan requested two weeks after sustaining it, a right dorsal trans-scaphoid perilunate fracture dislocation was identified. The affected area was therefore immobilized using forearm splinting and a surgery was scheduled.

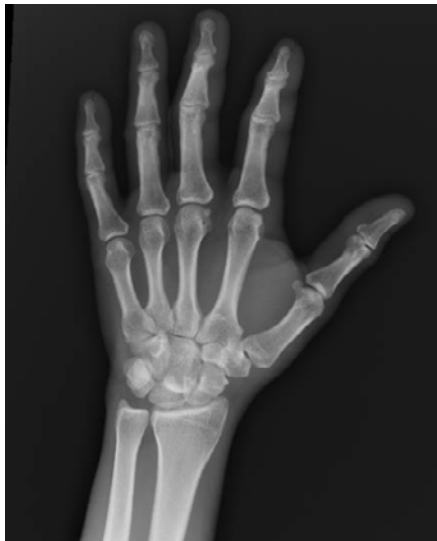

Figure 1. Anterior-posterior X-ray of the right hand after trauma. A right dorsal trans-scaphoid perilunate fracture dislocation is observed.

Source: Image obtained while the patient was being treated.

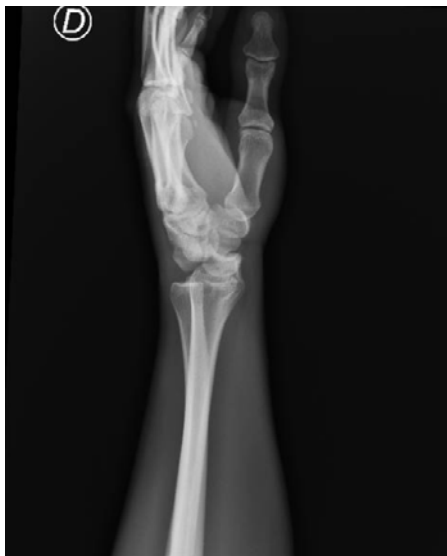

Figure 2. Lateral X-ray of the right wrist after the trauma. A dorsal trans-scaphoid perilunate fracture dislocation is observed.

Source: Image obtained while the patient was being treated.

Surgical procedure

Six weeks after the trauma, the patient underwent reconstructive surgery on his right hand and wrist. With the patient under regional anesthesia and in the supine position, a pneumatic tourniquet was applied to the right arm and the limb was placed on a hand table. Following limb emptying with an elastic bandage and increasing tourniquet pressure to 250 mmHg, a dorsal incision was made in the wrist, reaching the anatomical plane of the extensor tendons, which were separated to access the radiocarpal joint capsule. Next, the dorsal capsule was cut, creating a rectangular flap and preserving the dorsal radiocarpal and dorsal intercarpal ligaments, which allowed full exposure of the radiocarpal joint.

Kirschner wires were placed in the proximal and distal poles of the scaphoid to facilitate reduction of the trans-scaphoid perilunate fracture dislocation, and the scaphoid was fixed with two 2-mm cannulated screws. Scapholunate reduction was performed using two Kirschner wires; the scaphocapitate and lunotriquetral joints were reduced in the same fashion. In this way, carpal fixation was achieved in a diamond configuration, providing adequate stability. The scapholunate and dorsal intercarpal ligaments were repaired with augmentation using suture anchors. Subsequently, a dorsal capsulodesis was performed with high-strength sutures. Finally, through a palmar incision over the fourth finger, the transverse carpal ligament was exposed and incised in an “S” shape, allowing access to the carpal tunnel. A synovectomy of the flexor tendons and external neurolysis of the median nerve were performed, releasing the adhesions.

Immediately after surgery, follow-up X-rays (Figures 3 and 4) showed adequate reduction of the fracture dislocation with shaft recovery, no loss of joint congruence, and osteosynthesis material in the proper position. The patient was discharged 48 hours after surgery with indications for analgesic management (oral), immobilization with a volar forearm splint, and a follow-up appointment in 2 weeks. Four weeks after surgery, the percutaneous fixation with Kirschner wires was removed (Figures 5A and B), and the volar forearm splint was replaced with a wrist brace.

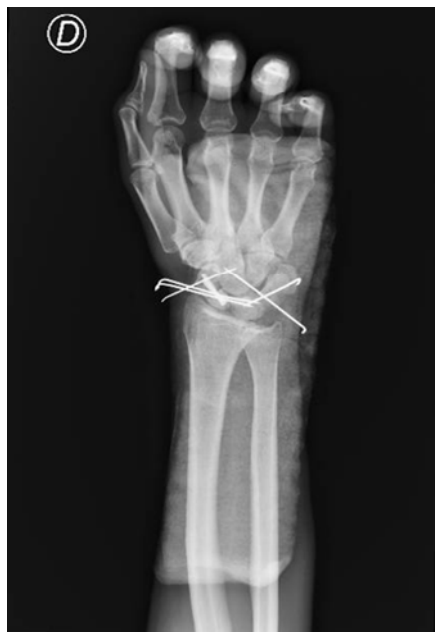

Figure 3. Anterior-posterior X-ray of the right hand and wrist taken immediately after surgery. Source: Image obtained while the patient was being treated.

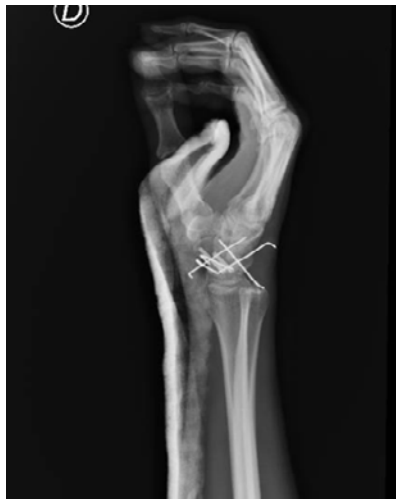

Figure 4. Lateral X-ray of the right hand and wrist taken immediately after surgery.
Source: Image obtained while the patient was being treated.

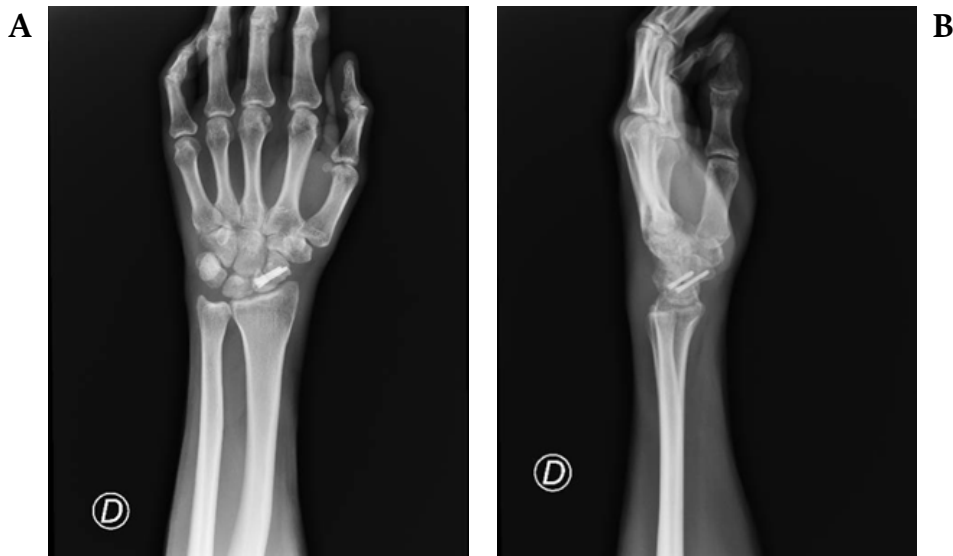


Figure 5. X-ray of the right wrist after removing percutaneous fixation (Kirschner wires).
A. Anterior-posterior X-ray. B. Lateral X-ray.
Source: Image obtained while the patient was being treated.

Results and follow-up

A follow-up X-ray taken 8 weeks after reconstructive surgery showed that the osteosynthesis material was in the proper position and that the scaphoid bone was in the process of healing. At the 16-week follow-up appointment, the patient reported complete resolution of pain and neuropathic symptoms, as well as adequate reintegration into his work activity. The physical examination showed full range of motion in the fingers, 45° wrist extension and flexion, and 45° and 80° wrist pronation and supination, respectively. No complications associated with the surgery were observed. The timeline of the case is illustrated in Figure 6.

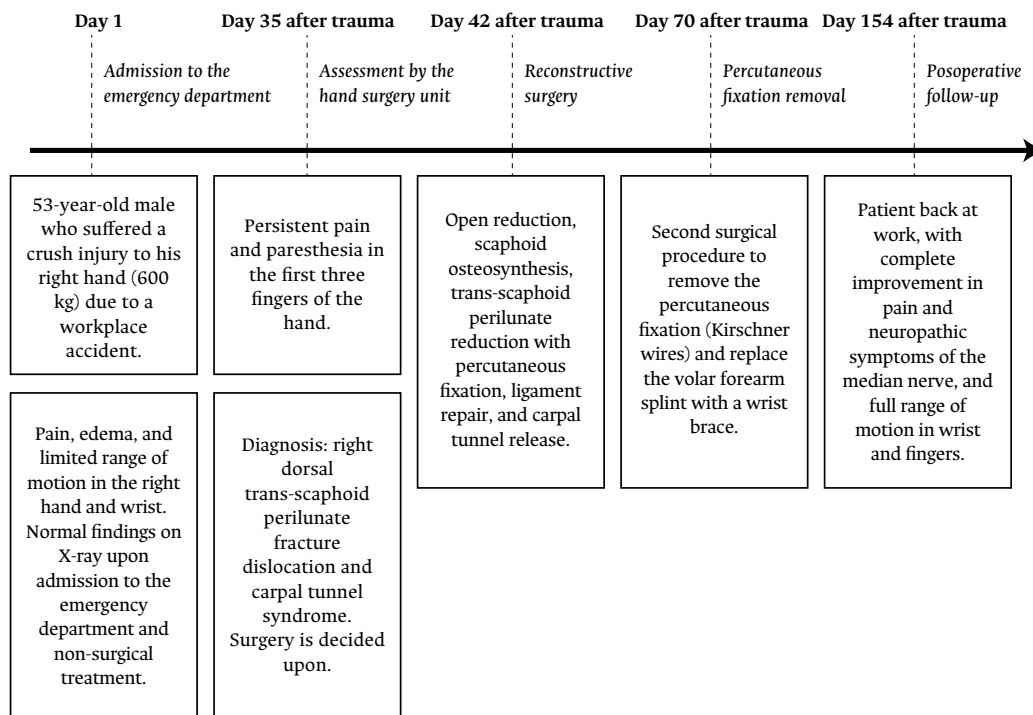


Figure 6. Case timeline.

Source: Own creation.

Discussion

Trans-scaphoid perilunate fracture dislocations are the most common type of complex carpal dislocation, accounting for 61% of perilunate dislocations and 96% of fracture dislocations.⁶ One of the main factors determining the prognosis of the injury is the period elapsed between the moment trauma occurred and when treatment started. If this period is >45 days, the injury is considered chronic and is associated with a worse clinical prognosis compared to those treated acutely.⁶ In the reported case, our patient underwent surgery six weeks after the trauma, as the injury was not identified during the initial assessment in the emergency department of another hospital. Although this factor may have contributed to the development of carpal tunnel syndrome, no adverse outcomes were noted at the last follow-up after 16 weeks. On the contrary, the patient returned to work and reported complete resolution of pain and neuropathic symptoms.

The most common mechanism of such injury is high-energy trauma, typically due to an axial load applied to an extended hand with the forearm in fixed pronation, causing hyperextension, intercarpal supination, and ulnar deviation of the wrist.⁷ Consequently, as a result of high-energy trauma, 10% of injuries are open wounds, 26% of cases present with multiple trauma, 11% suffer concomitant injuries to the ipsilateral upper limb, and 25% develop acute carpal tunnel syndrome.⁷ In our case, the patient sustained a crush trauma, a force that causes a dramatic increase in intracompartmental pressure that can cause severe damage to bones, blood vessels, nerves, and even soft tissues. Therefore, it is essential to evaluate these patients for compartment syndrome, as it is a potential complication.⁸ However, no findings suggestive of compartment syndrome were documented in our patient, who presented with acute carpal tunnel syndrome.

Patients with trans-scaphoid perilunate fracture dislocations usually present with limited range of motion in the wrist, pain, and swelling.⁹ Diagnosis is often difficult, and it is estimated that a quarter of cases are either undiagnosed or diagnosed late.

Therefore, authors such as Findlay *et al.*⁹ suggest that stress X-rays should be performed on patients admitted to emergency departments with crush injuries or suspected crush injuries to assess the presence of shaft disruption between the distal radius, the lunate, and the capitate, and make a timely diagnosis.⁹

The classical treatment for these injuries has been closed reduction and immobilization, but recent studies have shown that using them as definitive treatment can result in nonunion of the scaphoid, intercalary segmental instability, and wrist arthritis.¹⁰ As a result, other alternatives have been proposed, such as internal fixation, which has shown better outcomes.¹⁰

According to Kinghorn *et al.*,¹¹ the mainstay of treatment for these injuries are emergent reduction and close monitoring of the median nerve, followed by prompt stabilization and repair of the injured structures. According to Garg & Batra,⁵ the primary goal of managing chronic trans-scaphoid perilunate fracture dislocation is anatomic restoration of carpal alignment, and treatment modalities include open reduction and internal fixation, staged treatment using an external fixator, proximal row carpectomy, and wrist arthrodesis. Regarding the treatment implemented in our patient (open reduction and internal fixation), there is no consensus on the time limit for attempting open reduction of perilunate fracture dislocation without significant complications.⁵

Conclusions

This case report presents a man who developed CTS secondary to a chronic trans-scaphoid perilunate fracture dislocation caused by a high-energy trauma during a workplace accident, which was not identified on initial consultation to the emergency department, leading to a delay in diagnosis and treatment (five and six weeks after the trauma, respectively). Despite their low frequency, these injuries should be suspected after the occurrence of high-energy trauma affecting the carpus, as timely diagnosis and treatment are essential to prevent complications such as CTS and compartment syndrome.

Based on the outcomes reported in our patient, surgical management involving open reduction with internal fixation, ligament repair, and carpal tunnel release could be considered a therapeutic option in patients with chronic trans-scaphoid perilunate fracture dislocations and associated CTS.

Informed consent and ethical considerations

The patient signed an informed consent form authorizing the preparation and publication of this case report. In addition, this case report was approved by the Institutional Ethics Committee of the Clínica CES by means of approval document 105 dated May 26, 2023.

Conflicts of interest

None stated by the authors.

Funding

None stated by the authors.

Acknowledgements

The authors would like to thank Dr. Diana Restrepo Bernal for her assistance in writing and reviewing the manuscript.

References

1. Jansana JP, Tarrasón NV, Feliu IE *et al.* Fracturas, luxaciones y fracturas-luxaciones del carpo. In: Martínez FM, coordinator. *Traumatología y ortopedia. Miembro superior*. 1st ed. Spain: Elsevier Español; 2022. 244-254.
2. Lee SK, Bain GI, MacLean SBM, Lichtman DM. Fractures of the Carpal Bones. In: Wolfe S, Pedersosn WC, Kozin SH, Cohen MS. *Green's Operative Hand Surgery*. 8th edition. United States: Elsevier; 2021. 677-757.
3. Çolak I, Bekler HI, Bulut G, Eceviz E, Gülabi D, Çeçen GS. Lack of experience is a significant factor in the missed diagnosis of peri lunate fracture dislocation or isolated dislocation. *Acta Orthop Traumatol Turc*. 2018;52(1):32-6. doi: 10.1016/j.aott.2017.04.002. PMID: 29198546; PMCID: PMC6136336.
4. Patel AU, Thiara J, Rivas Z, Hansen SL. Descriptive epidemiology and management of perilunate injuries. *Ann Plast Surg*. 2024;93(4):447-50. doi: 10.1097/SAP.0000000000004093. PMID: 39331744.
5. Garg B, Batra S. Chronic trans-scaphoid peri lunate dislocation: Current management protocol. *J Clin Orthop Trauma*. 2020;11(4):523-8. doi: 10.1016/j.jcot.2020.05.006. PMCID: PMC7355076; PMID: 32684688.
6. Yildirim C, Unuvar F, Keklikci K, Demirtas M. Bilateral dorsal trans-scaphoid peri lunate fracture-dislocation: A case report. *Int J Surg Case Rep*. 2014;5(5):226-30. doi: 10.1016/j.ijscr.2014.02.006. PMID: 24705189; PMCID: PMC4008849.
7. Kim H-S, Oh W-T, Koh I-H, Choi Y-R, Kang H-J. Trans-scaphoid peri lunate fracture dislocation. *Arch Hand Microsurg*. 2021;26(2):69-81. doi: 10.12790/ahm.21.0080.
8. Goodman AD, Got CJ, Weiss APC. Crush injuries of the hand. *J Hand Surg Am*. 2017;42(6):456-63. doi: 10.1016/j.jhssa.2017.03.028. PMID: 28450098.
9. Findlay CM, Trinco DW, Eisenberg JM, Takacs ME. An isolated trans scaphoid peri lunate dislocation resulting from airbag deployment. *J Emerg Med*. 2021;60(6):796-7. doi: 10.1016/j.jemermed.2021.01.037.
10. Oh W-T, Choi Y-R, Kang H-J, Koh I-H, Lim K-H. Comparative outcome analysis of arthroscopic-assisted versus open reduction and fixation of trans-scaphoid peri-lunate fracture dislocations. *Arthroscopy*. 2017;33(1):92-100. doi: 10.1016/j.arthro.2016.07.018. PMID: 27707581.
11. Kinghorn A, Finlayson G, Faulkner A, Riley N. Peri lunate Injuries: Current Aspects of Management. *Injury*. 2021;52(10):2760-7. doi: 10.1016/j.injury.2021.09.012. PMID: 34717826.